

## INTRODUCTION

Mechanical submental liposuction technique, also known as submentoniana lipectomy (BALAJI; BALAJI, 2020), is a straightforward and common surgical procedure, being the technique of choice for this purpose. This method involves the use of a small-diameter and delicate cannula to remove localized fat accumulation in the neck, resulting in a more youthful and aesthetically pleasing contour between the chin and the neck. As mentioned by Prudente (2020), when no additional procedures are necessary, this intervention can be performed under local anesthesia on an outpatient basis. The procedure is carried out in the clinic using the tumescent anesthesia technique for enhanced safety during the procedure.

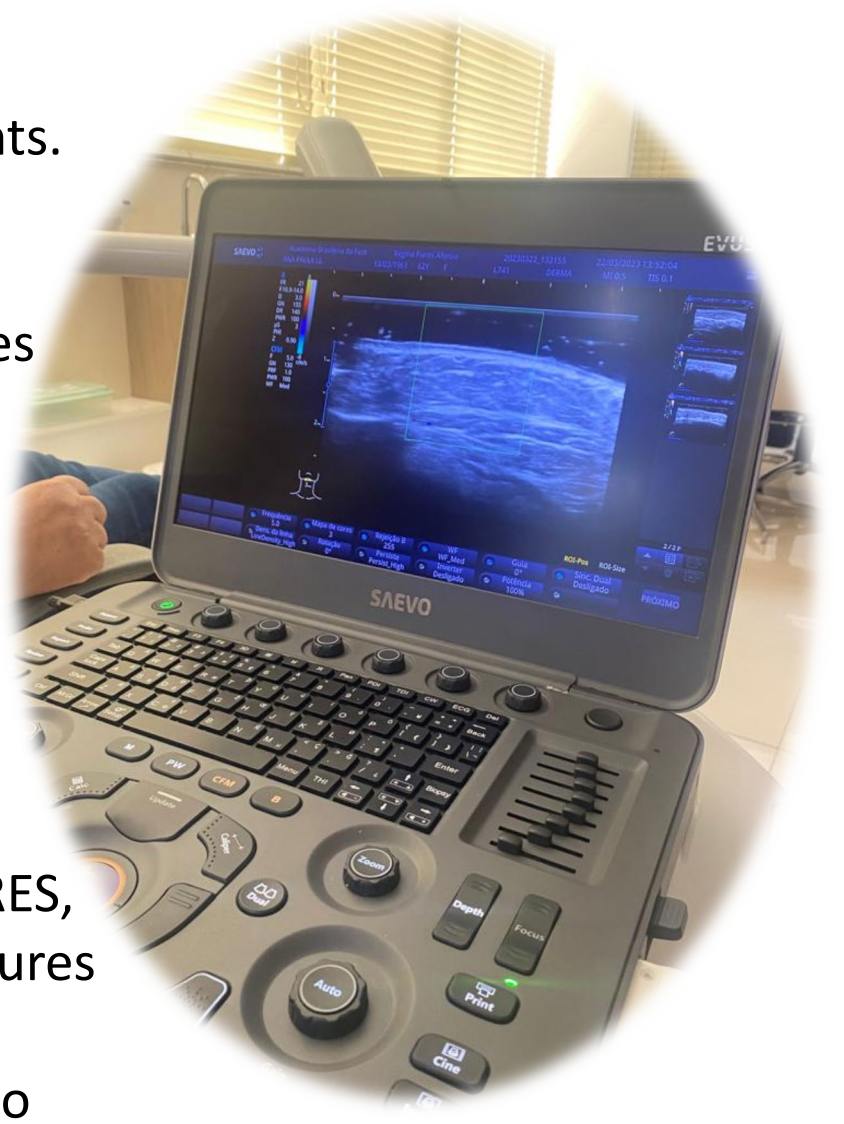
Liposuction is a notably simple procedure, often indicated based on factors such as the volume of submental fat, configuration and excess adipose tissue, breathing difficulties, psychosocial discomfort, unsatisfactory results from alternative treatments, the need for multiple sessions of enzyme-based lipolysis, among other elements that drive a more dynamic demand in this context (AVENA, DA ROCHA, & MACÁRIO, 2021). Hence, it becomes crucial to conduct a thorough assessment of medical history and perform a detailed physical examination of the patient to select the most suitable submental liposuction technique for each patient. This assessment aims to identify deformities, evaluate the aesthetic condition itself, and clearly understand the patient's expectations and desires, allowing for a better grasp of the available procedure options.

Ultrasound (USG) is an imaging examination that offers several advantages, such as being non-invasive, painless, and not using ionizing radiation, which provides a high level of safety. This examination is highly specific for assessing soft tissues and also allows for real-time Doppler flow assessment. Therefore, its use is extremely important, as it enables the evaluation of different layers of the face, including the epidermis, dermis, subcutaneous tissue, SMAS (superficial musculoaponeurotic system), and deep fat compartments. With patient safety in mind, this study will report a clinical case of submental liposuction surgery with a pre-surgical ultrasound examination to observe important anatomical structures of the submandibular region and measure the thickness of the supra-platysmal fat layer to be removed. An ultrasound examination was also repeated 45 days after the surgical intervention, confirming the successful fat removal and patient satisfaction.

## USE OF ULTRASOUND IN OROFACIAL HARMONIZATION

Ultrasound (US) is a diagnostic imaging examination that offers several advantages in medical practice. It is non-invasive, painless, and does not use ionizing radiation, making it safe for patients. This imaging technique is highly specific for visualizing soft tissues and also allows real-time assessment of blood flow through Doppler imaging. The use of ultrasound is crucial as it enables a detailed evaluation of various layers of the face, including the epidermis, dermis, subcutaneous tissue, SMAS (superficial musculoaponeurotic system), and deep fat compartments. Furthermore, the examination aids in identifying anatomical variations, vascular anastomoses, glands, and the presence of filler materials. Ultrasound provides precise information about facial structure and vascularization, contributing to a comprehensive and secure diagnosis. Hence, it is a valuable tool in clinical practice (SOARES, 2023). Ultrasound is an important tool to assist in liposuction procedures as it can provide qualitative images of soft tissues, including fat.

It is recommended that professionals request this examination prior to the procedure to assess the submental region and identify larger-caliber blood vessels, which is relevant for avoiding complications. Moreover, ultrasound is beneficial for measuring the thickness of localized fat in the submental area, allowing the dentist-surgeon to monitor treatment progress through pre- and post-measurements. It is essential to perform the examination both before and after treatment to track procedure evolution and verify fat reduction throughout the process.

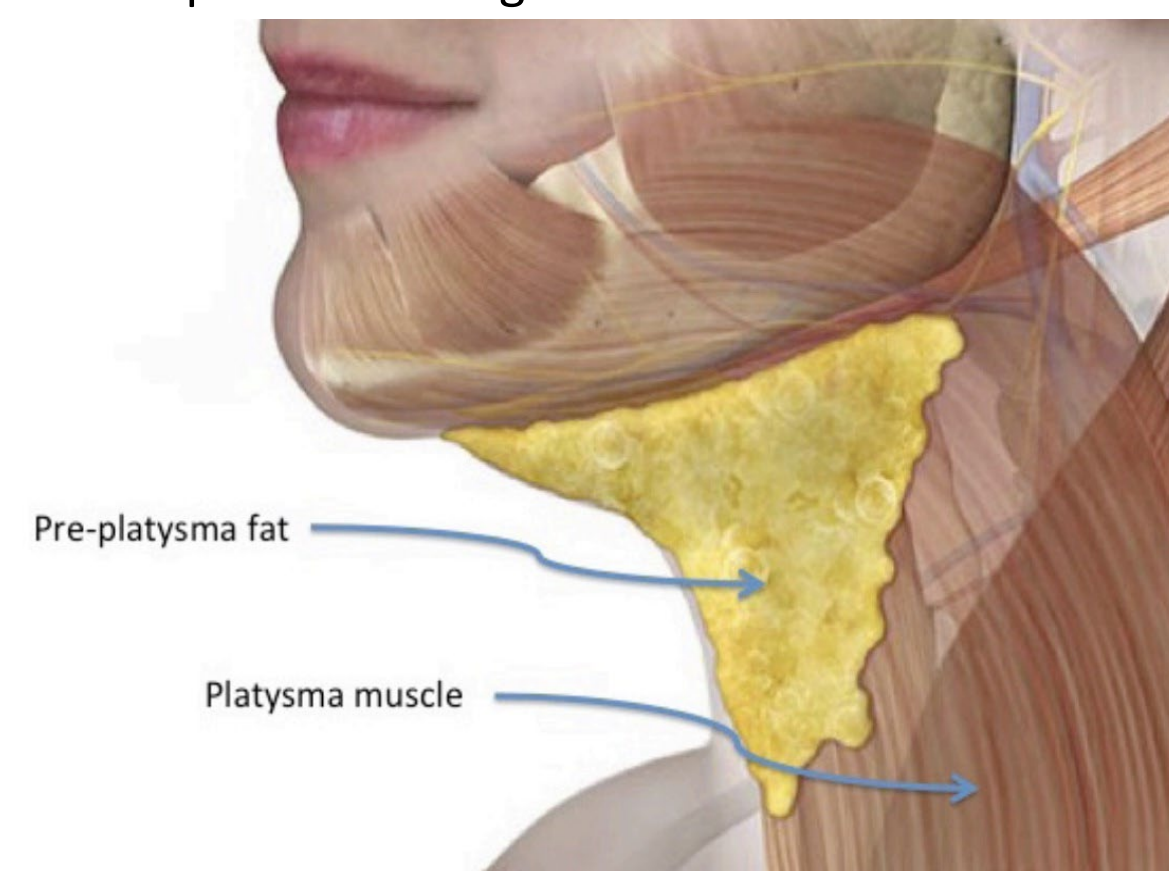


## ANATOMY OF THE SUBMANDIBULAR REGION

The aging process in the lower face and neck region is the result of a combination of genetic and environmental factors. Characteristics such as fair skin, excessive sun exposure, a history of smoking, inadequate jaw projection, accumulation of fat under the chin, and a low hyoid bone contribute to the aged appearance of the face and neck. As skin elasticity decreases, soft tissues begin to sag, fat atrophy and bone resorption occur, altering facial structure. The goal of rejuvenation in this region is to restore a more youthful appearance and create smooth transitions between the mid-face, jawline, and neck (FRISENDA, 2018).

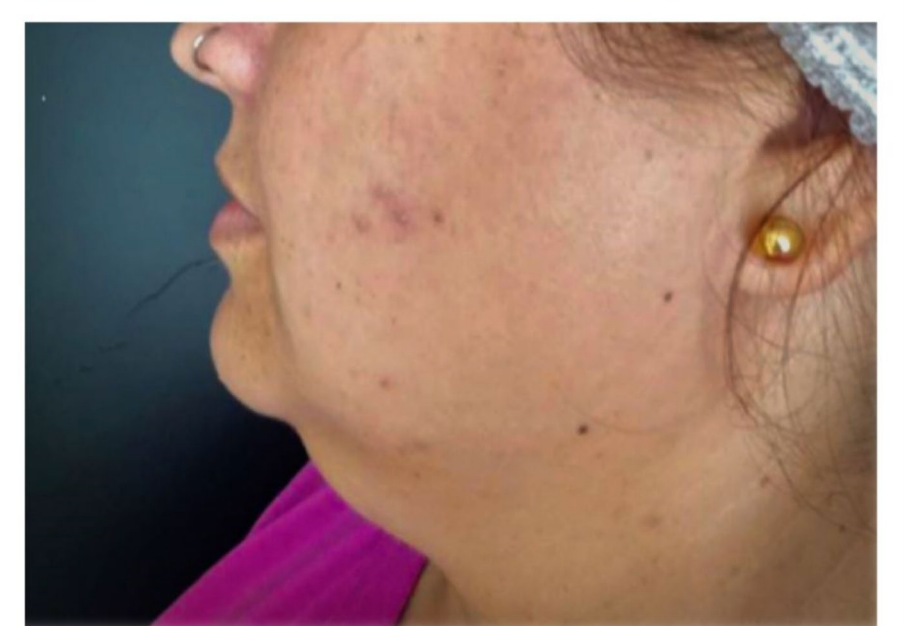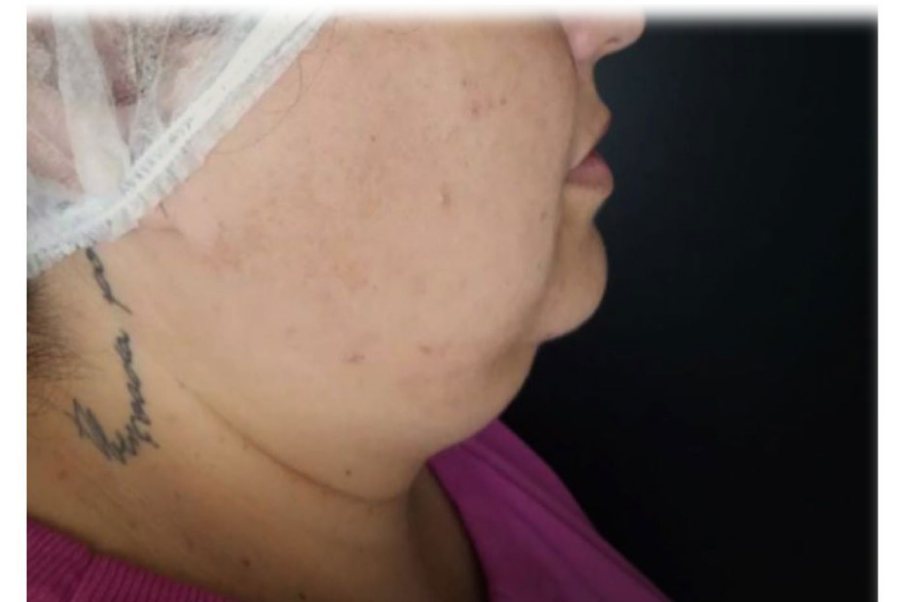According to Nanci (2018), submental fat accumulation is a common aesthetic issue affecting individuals of both sexes, including younger individuals. PRETTO et al. (2014) and Nanci (2018) stated that various factors can contribute to the development of a double chin, such as genetic predisposition, hormonal changes, the natural aging process, and excess weight. However, it's important to note that the complaint of a double chin can arise regardless of the patient's body mass index. PRETTO et al. (2014) added that the positioning of maxillary and mandibular bones and fat accumulation in the area can result in excess skin and adipose tissue beneath the jaw, causing the well-known "double chin" and generating discomfort and distress in patients. As a consequence, many individuals seek surgical procedures to improve the aesthetic aspect of this region.

A study conducted by Hatef DA et al. (2009) using cadavers revealed that the submental fat compartment is a discrete and areolar area located within the pre-platysmal fat layer. Superficially, this compartment is delimited by the dermis, while its deeper boundary is the platysma muscle. The submental crease is formed by the submental septum, constituting the anterior or medial border, and the hyoid septum forms the posterior or distal border. The digastric septa compose the lateral borders of the compartment. These findings should be considered for a visual and conceptual understanding of the anatomy of the submandibular region, in order to be fully utilized in aesthetic interventions.



## CASE REPORT

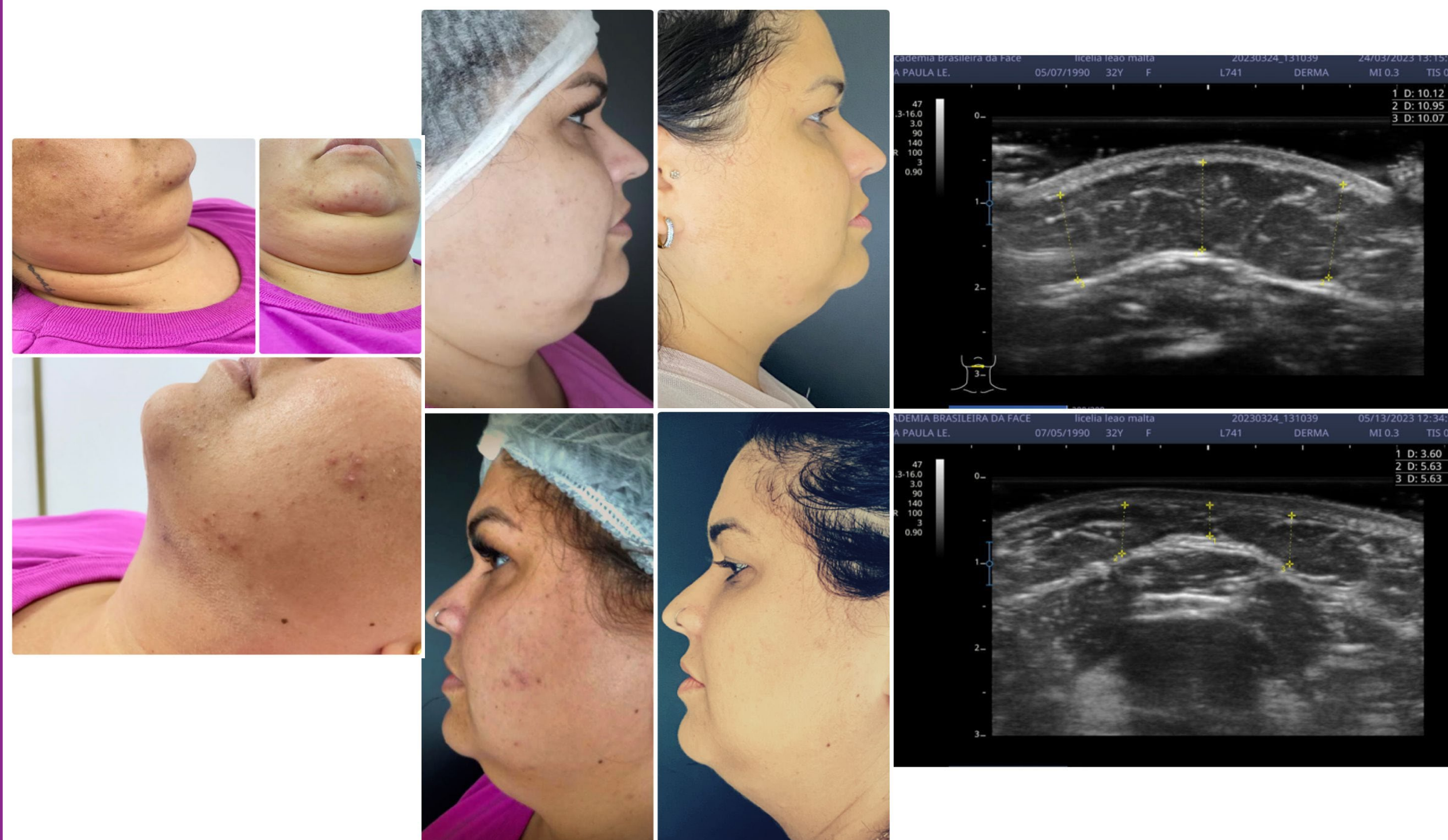
Patient L.L.M., a 32-year-old, presented at the clinic of the Brazilian Face Academy Institute in March 2023, expressing dissatisfaction with the aesthetics of her face in the submental area. Her main complaint was the excess adipose tissue in the area of the submental region, acquired due to weight gain, resulting in a double chin. She mentioned having undergone several sessions of lipolytic enzyme application in the area, and stated that she did not notice any difference in the treatment. The patient was adequately informed and instructed about the surgical procedure of mechanical submental liposuction and was informed about the treatment technique, risks, post-operative care, the need to also reduce the percentage of body mass index (% BMI), and was also clarified about the informed consent form, which were duly signed by her, including authorization for the use of images for research purposes and the creation of this scientific panel. The patient was operated on by Dr. Raphaela Gastin Pozzi, at the Brazilian Face Academy Institute, using the technique of liposuction with tumescent anesthesia solution.



Initial Patient Photo clearly showing the submandibular volume

## RESULTS

It is observed that in the initial ultrasound, there was a significant fat layer, measuring almost 11mm from all angles, along with flaccidity and an increased BMI as indicated in the medical history. In the ultrasound image taken 45 days after the surgical intervention, there is a decrease in this fat layer to 3.60mm in the anterior part of the submandibular region and 5.63mm when compared to the posterior region. This confirms a 63% reduction in fat, leaving a remaining thickness of 37% where the healing process is still ongoing due to the recent postoperative phase. Improvement is possible within up to 6 months.



## OBJECTIVE

The aim of this study was to highlight, through a clinical case report, one of the most commonly employed techniques in performing submental mechanical liposuction, combined with ultrasound examination to measure the thickness of the supra-platysmal fat layer, both in the preoperative and late postoperative stages.

## METHODS & MATERIAL

First, an initial consultation was conducted, including a medical history assessment, to better understand the patient, address questions, and provide clarifications. Subsequently, a physical examination, initial photographs, and ultrasound examination of the submental region were performed to evaluate important anatomical structures, such as the facial artery, platysma muscle thickness, submandibular gland, and, importantly, to measure the supra-platysmal fat layer thickness, the target of surgical removal.

Next, the Klein solution was prepared, consisting of 0.9% saline, 2% Lidocaine, Adrenaline, and 8.4% Sodium Bicarbonate. After allowing 10 minutes for proper dilution, the solution was applied to the intended liposuction area. Following this, the submental area was aseptically cleaned with 2% chlorhexidine and 70% alcohol to reduce skin microorganisms. Surgical marking points were then made in the double chin area using a surgical pen, indicating where the Klein solution would be applied. Subsequently, infiltrative anesthesia with 2% lidocaine hydrochloride and epinephrine (ALPHACAINE - DFL) was administered at the incision/perforation site to alleviate discomfort. This is the site where the cannula was introduced both for injecting the Klein solution and performing fat suction.

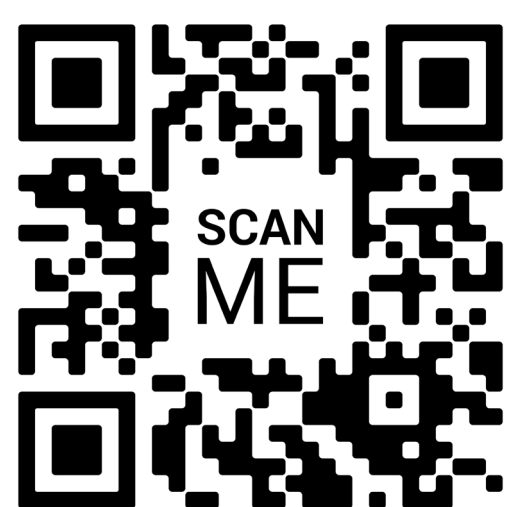After 20 minutes of Klein solution administration, the procedure commenced with liposuction in the infiltrated areas, corresponding to the submental region as delimited by the area of the dentist's intervention. The direction extended towards the cervical region, anterior border of the submental fold, posterior angle limit, and lateral limits below the mandibular crease. Liposuction was performed according to adipose tissue thickness. The initial supra-platysmal fat thickness, measured via ultrasound, averaged around 11mm in each region (anterior and posterior). Cannulas with an average diameter of 2.5mm to 3mm were used for fat breakdown and aspiration, with access incisions made at the anterior border of the submental fold. A dental vacuum pump and manual syringe were employed for effective suction.

Following the surgical procedure, sterile gauze compression was applied to remove excess fluid, and the perforation site was sutured with 6.0 nylon thread. Micropore tape and compressive dressing (kinesio) were used, with instructions for their use over the course of 5 days. Additionally, a head and neck compression garment was recommended for continuous wear for 15 days and then for sleep only for the subsequent 15 days, totaling 30 days. Crucially, 10 sessions of facial lymphatic drainage were prescribed to disperse fluids and facilitate tissue accommodation, given the absence of fat support to prevent potential complications such as fibrosis and bruising.

For the final case assessment, postoperative submental area photographs were taken. After 45 days, the patient was re-evaluated. An ultrasound examination was conducted for result monitoring, indicating successful outcomes compared to prior examinations. Notably, the patient expressed significant satisfaction with her current facial aesthetics. The initial ultrasound indicated a substantial fat layer, measuring almost 11mm from all angles. In contrast, the ultrasound image taken 45 days after the surgical intervention demonstrated a decrease in this fat layer to 3.60mm in the anterior part of the submandibular region and 5.63mm in the posterior region.

## CONCLUSION

The technique of minimally invasive liposuction employed in this study has demonstrated itself to be a safe, easily executed, reproducible method capable of delivering excellent aesthetic outcomes, which are immediate and, most importantly, aligned with the patient's expectations. The utilization of ultrasound examination was pivotal in validating the extent of supra-platysmal fat removal, yielding highly satisfactory results and confirming the surgical objective was successfully achieved with both effectiveness and safety. It should be emphasized that the patient is aware that to attain a satisfactory aesthetic outcome, further types of treatment will be necessary, including body mass index reduction and addressing the region's skin laxity, subsequent to the final surgical outcome.



## REFERENCES